

Bone quality in relation to skeletal maturation in palatal miniscrews insertion sites

Camilla Braga, Lucia Pozzan, Carlo Ciotola, Chiara Viganoni, Lucio Torelli, and Luca Contardo,
Trieste, Italy

Introduction: This study aimed to investigate the relationship between bone density and quantity at the insertion sites of palatal miniscrews and skeletal maturation—evaluated with the middle phalanx maturation method—in growing patients. **Methods:** Sixty patients were analyzed as having a staged third finger middle phalanx radiograph and a cone-beam computed tomography of the maxilla. On the cone-beam computed tomography, a grid was designed to parallel the midpalatal suture (MPS) and posterior to the nasopalatine foramen, both on the palatal and lower nasal cortical bones. Bone density and thickness were measured at the intersections, and medullary bone density was also calculated. **Results:** Of patients in MPS stages 1-3, 67.6% showed a mean palatal cortical thickness of <1 mm, whereas in 78.3% of the patients in stages 4 and 5, it was >1 mm. The nasal cortical thickness showed a similar trend (MPS stages 1-3: 62.16% <1 mm; MPS stages 4 and 5: 65.2% >1 mm). There was a significant difference in the density of the palatal cortical bone between MPS stages 1-3 (1272.05 ± 191.13) and stages 4 and 5 (1572.33 ± 274.89) and in nasal cortical density between MPS stages 1-3 (1428.09 ± 198.97) and stages 4 and 5 (1597.97 ± 267.75) ($P < 0.001$). **Conclusions:** This study revealed a correlation between skeletal maturity and maxillary bone quality. MPS stages 1-3 have lower palatal cortical bone density and thickness but high nasal cortical bone density values. MPS stage 4 and, even more, stage 5 show increasing palatal cortical bone thickness and palatal and nasal cortical bone density values. (Am J Orthod Dentofacial Orthop 2023; ■: ■-■)

Palatal miniscrews have gained increasing popularity¹⁻³ in modern orthodontics. Miniscrews are skeletal devices that enhance biomechanics during orthodontic treatments, providing absolute anchorage.⁴ Compared with other insertion sites, the palatal area is considered safer because noble structures such as nerves and arteries are absent.⁵ A thick keratinized mucosa makes it a more reliable insertion site for nonkeratinized mucosa.^{6,7} All of these factors contribute to lower failure rates for palatal insertion.⁸

Bone density and quantity at the palatal insertion sites have been investigated in cone-beam computed tomography (CBCT) and computed tomography (CT) scans mainly in adult patients,⁹⁻¹¹ showing that better bone

quality can be found 3-6 mm paramedian to the suture and 6-9 mm distal to the incisal foramen.¹¹

Because most orthodontic treatments are performed in adolescents, some authors also investigated bone volume in growing patients,^{12,13} whereas others compared CBCT scans of adults and adolescents to assess age differences in bone quality. Farnsworth et al¹⁴ compared CBCT images of 26 adolescents and 26 adults, finding mean cortical thickness values of 1.25 ± 0.28 mm, 1.07 ± 0.28 mm, 0.98 ± 0.39 mm, respectively, at 3, 6, and 9 mm dorsal and 3 mm lateral to the incisive foramen. The authors found a higher bone thickness in adult patients, concluding that age-related differences in cortical bone thickness could be related to hormonal factors¹⁵ and increased muscular activity.¹⁶⁻¹⁹ In contrast, Han et al²⁰ compared 60 adolescents and 60 adults to assess age differences in cortical and cancellous bone density. In this study, adults showed a significantly higher density (816 ± 15 Hounsfield units [HU]) than adolescents (606 ± 14 HU). Similarly to cortical bone, cancellous bone showed a significantly higher bone density in adults (154 ± 7 HU) than in adolescents (135 ± 5 HU).

From the Department of Medicine, Surgery and Health Sciences, University of Trieste, Trieste, Italy.

All authors have completed and submitted the ICMJE Form for Disclosure of Potential Conflicts of Interest, and none were reported.

Address correspondence to: Lucia Pozzan, SC (UCO) Clinica di Chirurgia Maxillo-facciale e Odontostomatologia, Ospedale Maggiore, Piazza Ospitale 1, Trieste 34129, Italy; e-mail, lucia.pozzan@phd.units.it.

Submitted, October 2022; revised and accepted, February 2023.

0889-5406/\$36.00

© 2023 by the American Association of Orthodontists. All rights reserved.

<https://doi.org/10.1016/j.ajodo.2023.02.013>

However, these studies based their patient's selection on chronological age, which has previously been proven unreliable growth markers.²¹⁻²³ The third finger middle phalanx maturation (MPM) method is a reliable alternative to assess skeletal age. This system has gained popularity among orthodontists because minimal radiation exposure and easy execution and interpretation allow for close monitoring of the ossification events.²⁴ The MPM method is a consistent growth indicator with good diagnostic accuracy in identifying the mandibular growth peak.^{24,25}

Therefore, this study investigated the relationship between bone quality at the palatal insertion sites and skeletal maturation evaluated with the MPM method in growing patients. The long-term goal is to gain some insight into the influence of bone quality on the stability of miniscrews placed in the palate of growing patients and to understand some possible clinical implications and indications for a bicortical insertion. The null hypothesis is that there is no relationship between bone quality, represented by density and thickness, and skeletal maturation stages.

MATERIAL AND METHODS

The database of the Orthodontics Section of the Department of Medical, Surgical, and Health Sciences of the University of Trieste (Italy) was screened, considering files collected between January 2015 and December 2021. The sample for this study included subjects seeking orthodontic treatment whose signed informed consent was obtained; the protocol was reviewed and approved by the Ethical Committee of the University of Trieste (protocol code no. 122, approved May 23, 2022).

The following inclusion criteria were applied: (1) aged 8-16 years, (2) absence of anomalies in the maxillary region, (3) good general health, and (4) no history of trauma in the maxillary region. In contrast, the following exclusion criteria were applied: (1) radiographs of poor diagnostic quality, (2) subjects with known craniofacial (or other) conditions or syndromes, (3) scans with palatal impacted permanent teeth in the quadrant measured, and (4) previous orthodontic treatment.

For each subject, a third finger middle phalanx radiograph was taken as part of the routine clinical recording, and a CBCT (Hyperion X9; My-Ray, Imola-Bo, Italy) was taken as a second-level diagnostic investigation to evaluate the position of impacted teeth or the insertion sites for palatal miniscrews. For each patient, the right quadrant of the maxilla was chosen, and whenever the scans presented unerupted teeth on the right side of the maxilla, the left quadrant was analyzed. Only 1 side of

the maxilla was considered, according to the literature's suggestion that there are no significant differences in cortical thickness and bone density between the 2 sides.^{9,26-28}

A total of 60 patients were selected. The mean age of the sample was 12.25 ± 1.82 years. Of these 60 patients, 11 were staged midpalatal suture (MPS) stage 1 (mean age 10.27 ± 1.42 years), 14 were MPS stage 2 (mean age 11.21 ± 1.31 years), 12 were MPS stage 3 (mean age 12.92 ± 0.79 years), 10 were MPS stage 4 (mean age 12.80 ± 1.13 years), and 13 were MPS stage 5 (mean age 14.00 ± 1.53 years). CBCT (60-90 kV; 4-10 mA; 0.5 mm voxel size; scan time 18 s; and field view of no more than $108 \text{ mm} \times 80 \text{ mm}$, $108 \times 50 \text{ mm}$) scans were imported into a medical image viewer (version 3.3.6; Horos Open-Source Medical Image Viewer) to analyze digital imaging and communications in medicine files. Before the measurements, each site was oriented in all 3 planes of space (Fig 1). The nasopalatine foramen and the MPS were chosen as radiographic landmarks for the analysis. A grid was designed with 3 lines 3, 6, and 9 mm lateral and parallel to the MPS and 3 perpendicular lines 3, 6, and 9 mm dorsal to the posterior limit of the nasopalatine foramen, as previously described by Ludwig et al.⁵ The same grid was drawn on the nasal cortical plane (Figs 2-3). The intersection points were evaluated, and bone density and thickness were measured at each of the 9 points of the oral and nasal cortical bones. To account for the lack of homogeneity of the trabecular bone, the medullary bone density was calculated as the mean bone density of a region of interest. Lines connecting the corresponding points of the 2 grids were drawn on the oral and nasal cortical plates. Horos software calculated the mean bone density for each line (Fig 4). Bone density was calculated in gray density units, and all CBCT scans were performed by the same CBCT scan machine (Hyperion X9) with the same settings for all patients. The MPM stage was evaluated for each third finger middle phalanx radiograph according to the stages described by Perinetti et al.²⁵ (Table 1; Fig 5).

Statistical analysis

The sample size of 11 subjects per group was calculated to detect an effect size of 1.3 in the difference between 2 independent means in palatal cortical density between MPS stages 1-3 and 4 and 5.

The thickness and density values of the 9 points considered in each region were averaged. After verifying the required assumption for sample normality with the Shapiro-Wilk test, intergroup differences in palatal and nasal cortical density and medullary density were

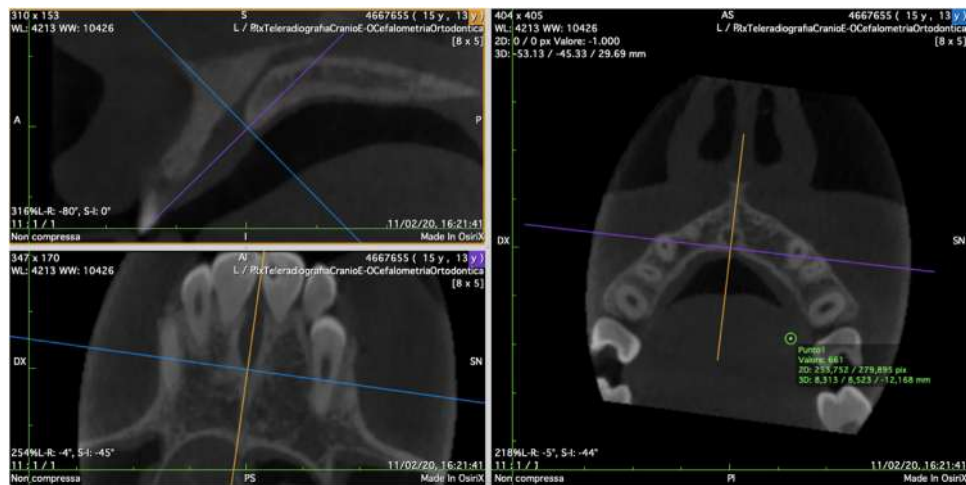


Fig 1. Before measurement, each site was oriented in all 3 planes of space. The sagittal axis was oriented according to the MPS, whereas the frontal and the transversal axes were oriented parallel and perpendicularly to the anterior palatine vault in the palatal rugae area in which miniscrews are usually positioned. MPS, midpalatal suture.

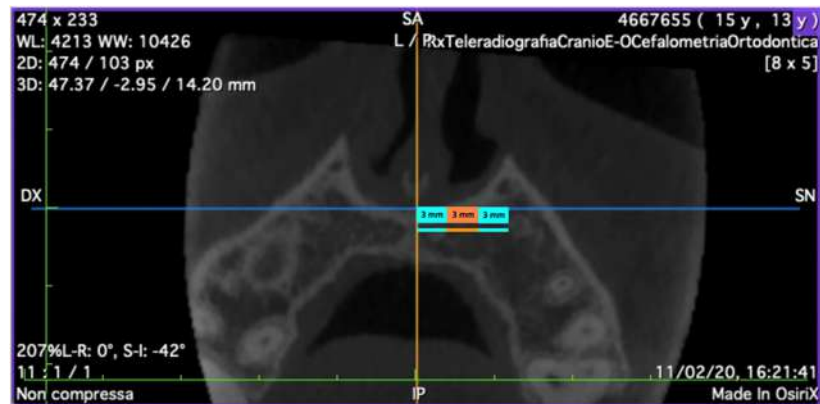


Fig 2. The axial slice defined 3 points 3, 6, and 9 mm to the midline. The sagittal slice was then moved 3, 6, and 9 mm.

evaluated using the independent sample *t* test, whereas a 1-way analysis of variance (ANOVA) test with Tukey's correction was used to evaluate the effects of skeletal maturation on palatal cortical and medullary density and nasal cortical density. A chi-square test of independence was performed to assess the relationship between palatal and nasal cortical thickness and MPM stages, using a thickness cutoff of 1 mm.²⁹ A paired-sample *t* test was performed to assess the significance of the difference between palatal and nasal cortical density for MPM stages from MPS stages 1-5. Finally, the Pearson correlation coefficient was calculated to correlate oral

and nasal cortical density values to their third finger middle phalanx values. All data were analyzed with Jasp (version 0.16.1.0; Jasp Team 2022, Department of Psychological Methods, University of Amsterdam, Amsterdam, The Netherlands, www.jasp-stats.org/), and a significance level of 5% was considered for all tests. Repeatability analysis was performed on a subset of 30 samples randomly chosen and assessed at 2 different time points by the 2 raters (C.B., C.C.). After testing the existence of a normal distribution of the datasets, the intraclass correlation coefficient (ICC) was used for the analysis. A 2-way random-effect model

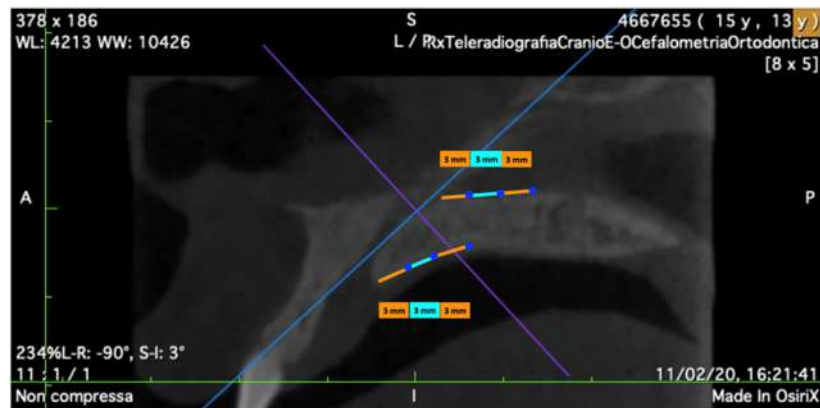


Fig 3. For each sagittal slice, points at 3, 6, and 9 mm dorsal to the nasopalatine foramen were evaluated on the oral and nasal cortical bones.

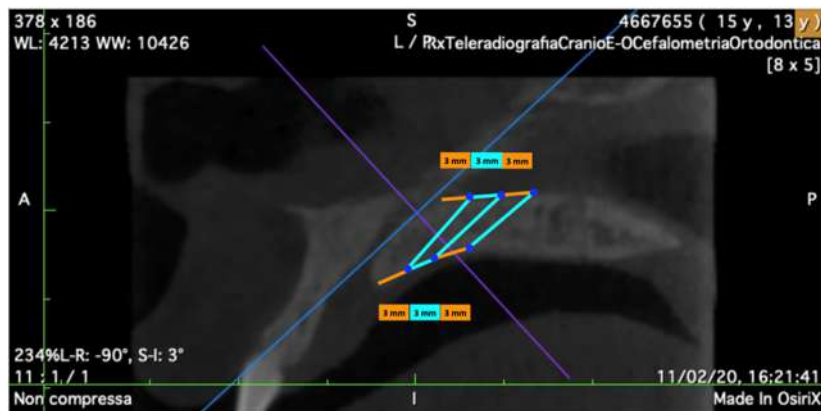


Fig 4. The software measured medullary bone density, which calculated the mean bone density (gray density units) in vertical lines through the corresponding points of the 2 grids.

based on single ratings and absolute agreement assessed the interrater repeatability, and a 2-way mixed-effect model based on a single rating assessed the intrarater repeatability for rater 1. Mean values and 95% confidence intervals (CI) were reported. The interpretation was as follows: poor, <0.50 ; fair, $0.50-0.75$; good, $0.75-0.90$; and excellent, >0.90 .

Maximal rates of bone mineral accrual follow height peak by approximately 6-12 months.³⁰ Consequently, at the peak in height, patients reach approximately 90% of their adult height, but they have acquired only 60% of their adult total body mineral content, resulting in relatively less mineralized bone.^{30,31} Therefore, patients were grouped between MPS stages 1-3 (patients before the growth peak and in the ascending phase of the peak spurt) and stages 4 and 5 (after the growth peak and at the end of the pubertal growth spurt).

RESULTS

The ICC for intrarater repeatability is considered excellent for all measurements analyzed, being 0.96 (0.92-0.98) for oral cortical density, 0.97 (0.95-0.99) for nasal cortical density, 0.97 (0.96-0.98) for medullary density and 0.93 (0.89-0.95) for cortical thickness. For interrater reliability, the ICC was excellent for oral cortical density 0.96 (0.92-0.97), nasal cortical density 0.97 (0.94-0.98), medullary density 0.97 (0.96-0.98), and good for cortical thickness 0.86 (0.79-0.91).

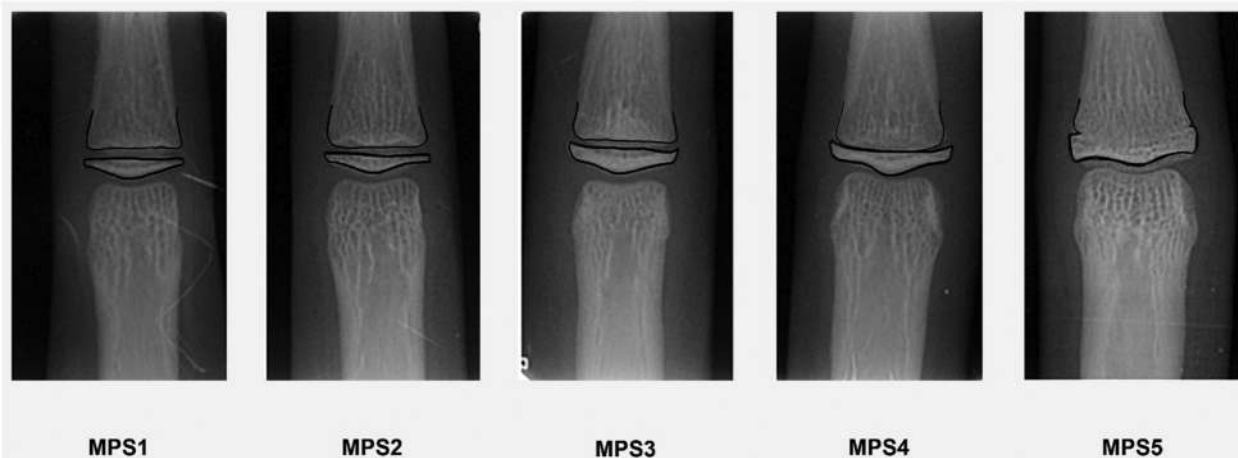
Table II shows the mean values (95% CI, standard deviation, and minimum and maximum value) of the palatal and nasal cortical thickness divided according to the MPM stage (Table II).

Assessment of the relationship between MPS stages 1-3 and 4 and 5 and cortical thickness using the chi-square test showed a significant relationship between

Table I. Description of the stages of the third finger middle phalanx maturation (MPM) method according to Perinetti et al¹⁹

| MPS stage | Attainment |
|--|--|
| 1: Epiphysis is narrower or as wide as the metaphysis, but both lateral borders are tapered and rounded. Epiphysis and metaphysis are not fused | >1 y before the mandibular growth peak |
| 2: Epiphysis is at least as wide as the metaphysis, with sides increasing thickness and showing a clear line of demarcation at a right angle. In case of asymmetry between the 2 sides, the more mature side is used to assign the stage | 1 y before the mandibular growth peak |
| 3: Epiphysis is either as wide as or wider than the metaphysis, with lateral sides showing an initial capping toward the metaphysis. Epiphysis and metaphysis are not fused | Coincidental with the mandibular growth peak |
| 4: Epiphysis begins to fuse with the metaphysis, but the contour is still recognizable | After the mandibular growth peak |
| 5: Epiphysis is fused with the metaphysis | At the end of a pubertal growth spurt |

MPS, midpalatal suture.

**Fig 5.** Clinical example of the stages of the third finger MPM method according to Perinetti et al.²⁵ MPS, midpalatal suture; MPM, middle phalanx maturation.

the 2 variables both for palatal cortical thickness ($\chi^2 [1, n = 60] = 11.92, P < 0.001$), and for nasal cortical thickness ($\chi^2 [1, n = 60] = 4.26, P < 0.04$) (Table III).

Comparing the effect of skeletal maturity using the MPM method on mean palatal cortical density, ANOVA tests revealed that there was a statistically significant difference in mean density between at least 2 groups ($F[4, 55] = [6.93], P < 0.001$). Tukey's honest significance test for multiple comparisons found that the mean value of palatal cortical density was significantly different between MPS stage 1 and 5 (95% CI = -649.72 to -125.53 ; $P = 0.001$), between MPS stage 2 and 5 (95% CI, -620.98 to -128.16 ; $P = 0.001$), and between MPS stage 3 and 5 (95% CI, -594.74 to -82.52 ; $P = 0.004$). There were no statistically

significant differences in mean palatal cortical density between the other stages (Table IV).

An independent samples *t* test revealed a significant difference in the density of the palatal cortical between MPS stages 1-3 (1272.05 ± 191.13) and 4 and 5 (1572.33 ± 274.89) (t [degrees of freedom (df)] = 58.00; $P < 0.001$), and also in palatal medullary density between MPS stages 1-3 (639.47 ± 223.37) and 4 and 5 (775.61 ± 305.82) (t [df] = 58.00; $P = 0.05$).

Regarding the relationship between skeletal maturity and mean nasal cortical density, a 1-way ANOVA revealed a statistically significant difference in mean density between at least 2 groups ($F[4,55] = 3.50$; $P = 0.013$). Tukey's honest significance test for multiple comparisons found that the mean value of nasal cortical

Table II. Descriptive statistics for palatal and nasal cortical thickness divided according to MPM stage

| Variables | Mean ± SD | Minimum | Maximum | 95% CI |
|--|-------------|---------|---------|-----------|
| Palatal cortical thickness (mm) | | | | |
| MPS 1 | 0.98 ± 0.14 | 0.84 | 1.31 | 0.88-1.07 |
| MPS 2 | 0.94 ± 0.15 | 0.69 | 1.27 | 0.85-1.03 |
| MPS 3 | 0.92 ± 0.20 | 0.75 | 1.47 | 0.80-1.05 |
| MPS 4 | 1.14 ± 0.21 | 0.82 | 1.55 | 0.99-1.30 |
| MPS 5 | 1.11 ± 0.26 | 0.74 | 1.60 | 0.95-1.27 |
| Nasal cortical thickness (mm) | | | | |
| MPS 1 | 1.04 ± 0.12 | 0.92 | 1.28 | 0.96-1.12 |
| MPS 2 | 0.95 ± 0.13 | 0.77 | 1.27 | 0.87-1.03 |
| MPS 3 | 0.93 ± 0.19 | 0.62 | 1.21 | 0.81-1.04 |
| MPS 4 | 1.07 ± 0.15 | 0.81 | 1.35 | 0.95-1.18 |
| MPS 5 | 1.00 ± 0.22 | 0.59 | 1.39 | 0.87-1.14 |

SD, standard deviation; MPS, midpalatal suture; MPM, middle phalanx maturation.

Table III. Contingency tables for palatal and nasal cortical thickness grouping MPS stages 1-3 and 4 and 5 and using a thickness cutoff of 1 mm

| Variables | Thickness | | Total |
|-----------------------------------|-----------|------|-------|
| | <1 | >1 | |
| Palatal cortical thickness | | | |
| MPS 1-3 | | | |
| Count | 25 | 12 | 37 |
| % | 67.6 | 32.4 | 100 |
| MPS 4 and 5 | | | |
| Count | 5 | 18 | 23 |
| % | 21.7 | 78.3 | 100 |
| Total | | | |
| Count | 30 | 30 | 60 |
| % | 50.0 | 50.0 | 100 |
| Nasal cortical thickness | | | |
| MPS 1-3 | | | |
| Count | 23 | 14 | 37 |
| % | 62.16 | 37.8 | 100 |
| MPS 4 and 5 | | | |
| Count | 8 | 15 | 23 |
| % | 34.8 | 65.2 | 100 |
| Total | | | |
| Count | 31 | 29 | 60 |
| % | 51.7 | 48.3 | 100 |

MPS, midpalatal suture.

Table IV. Descriptive statistics for palatal cortical density according to MPM stage

| Variables | Mean ± SD | Minimum | Maximum | 95% CI |
|-----------|------------------|---------|---------|-----------------|
| MPS 1 | 1251.22 ± 247.40 | 908.11 | 1620.67 | 1085.02-1417.43 |
| MPS 2 | 1264.28 ± 167.35 | 987.55 | 1501.22 | 1167.65-1360.91 |
| MPS 3 | 1300.21 ± 171.58 | 998.00 | 1643.89 | 1191.20-1409.23 |
| MPS 4 | 1485.85 ± 217.70 | 1139.44 | 1900.55 | 1330.12-1641.59 |
| MPS 5 | 1638.85 ± 303.25 | 1113.44 | 2096.89 | 1455.59-1822.10 |

SD, standard deviation; MPM, middle phalanx maturation; MPS, midpalatal suture.

Table V. Descriptive statistics for nasal cortical density according to MPM stage

| Variables | Mean ± SD | Minimum | Maximum | 95% CI |
|-----------|------------------|---------|---------|-----------------|
| MPS 1 | 1424.13 ± 153.32 | 1112.78 | 1645.44 | 1321.13-1527.13 |
| MPS 2 | 1379.83 ± 182.96 | 996.89 | 1675.33 | 1274.19-1485.47 |
| MPS 3 | 1488.01 ± 248.48 | 1034.33 | 1990.55 | 1330.13-1645.88 |
| MPS 4 | 1489.63 ± 112.18 | 1305.44 | 1633.11 | 1409.38-1569.88 |
| MPS 5 | 1681.30 ± 323.56 | 1156.11 | 2237.00 | 1485.77-1876.82 |

SD, standard deviation; MPM, middle phalanx maturation; MPS, midpalatal suture.

density was significantly different between MPS stage 1 and 5 ($P = 0.05$; 95% CI, -514.06 to -0.27), between MPS stage 2 and 5 (95% CI, -542.99 to -59.94 ; $P = 0.007$). There were no statistically significant differences in mean palatal cortical density between the other stages (Table V).

An independent samples t test revealed a significant difference in nasal cortical density between MPS stages 1-3 (1428.09 ± 198.97) and 4 and 5 (1597.97 ± 267.75) ($t[df] = 58.00$; $P < 0.001$).

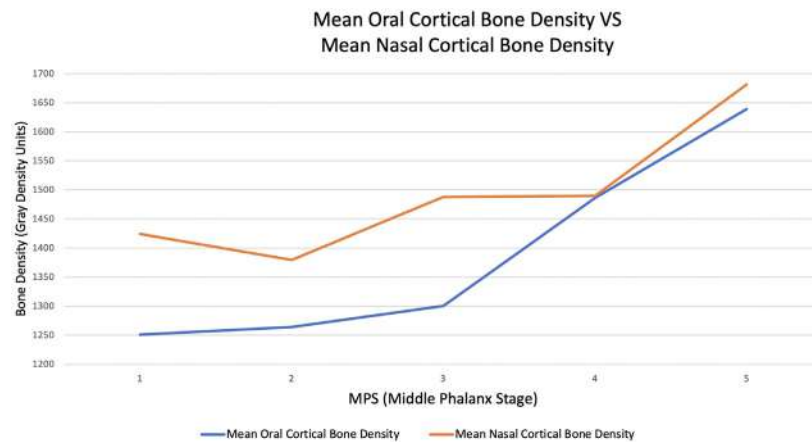
Comparing the effect of skeletal maturity using the MPM method on the mean density of the palatal medullary bone, ANOVA tests did not reveal statistically significant differences in mean density between any of the groups (Table VI).

According to the Pearson correlation coefficient, there was a positive correlation between both the oral and nasal cortical density and MPM stages (oral cortical

Table VI. Descriptive statistics for palatal medullary density according to MPM stage

| Variables | Mean \pm SD | Minimum | Maximum | 95% CI |
|-----------|---------------------|---------|---------|----------------|
| MPS 1 | 639.64 \pm 214.14 | 320.22 | 881.00 | 495.78-783.49 |
| MPS 2 | 571.01 \pm 201.90 | 200.44 | 978.22 | 454.44-687.59 |
| MPS 3 | 719.18 \pm 246.02 | 318.00 | 989.11 | 562.86-875.49 |
| MPS 4 | 722.64 \pm 274.30 | 360.11 | 1189.78 | 526.42-918.87 |
| MPS 5 | 816.35 \pm 333.01 | 378.00 | 1539.78 | 615.11-1017.59 |

SD, standard deviation; MPM, middle phalanx maturation; MPS, midpalatal suture.

**Fig 6.** Mean oral cortical bone density vs mean nasal cortical bone density (gray density units).

density: $r [58] = 0.54, P < 0.001$; nasal cortical density: $r [58] = 0.39, P = 0.002$.

Finally, paired-sample t tests revealed a significant difference in mean density between palatal cortical and nasal cortical for MPS stage 1 (palatal: 1251.22 ± 247.40 ; nasal: 1424.13 ± 153.32) ($P = 0.05$), stage 2 (palatal: 1264.28 ± 167.36 ; nasal: 1379.83 ± 182.96) ($P < 0.001$), and stage 3 (palatal: 1300.21 ± 171.58 ; nasal: 1488.01 ± 148.48) ($P = 0.03$). No statistical differences were found for MPS stages 4 and 5 (Fig 6).

DISCUSSION

Bone quality is an important factor affecting dental implants and miniscrews: bone density and cortical thickness are key factors in primary stability.^{8,29,32,33} A CT scan is commonly used for quantitative and qualitative preoperative evaluation of bone quality, and the HU is used to objectively determine bone density.³⁴⁻³⁶ The recent introduction of CBCT imaging has revolutionized oral and maxillofacial imaging,³⁶ because good spatial resolution, dimensional accuracy, and gray density range and contrast are now achievable with cheaper protocols that provide a lower radiation dose.³⁷ However, unlike CT, the gray density values of CBCT images (voxel value) are not absolute, differing

from one x-ray device to another.³⁷ Therefore, the values should not be considered absolute, but because CBCT scans evaluated in this study were taken by the same CBCT unit, a qualitative assessment of the bone density trend throughout the different stages was possible. Furthermore, to date, the literature has not given a CT HU reference value to predict the primary stability of the miniscrew.

Cortical thickness has been related to the primary stability of miniscrews and implants.³⁸⁻⁴³ Cortical bone thickness of at least 1 mm has proven to be a key factor in primary stability and is considered by some authors to be sufficient to guarantee the primary stability of miniscrews.⁴² In contrast, many studies have shown a correlation between the primary stability of miniscrews and cortical²⁹ and cancellous bone density.⁴⁴

This study measured and divided palatal and nasal cortical thickness according to the patients' MPM stage from 1 to 5 (Table II). The mean thickness of the palatal cortical was < 1 mm in MPS stages 1-3, whereas it was > 1 mm in stages 4 and 5. A similar trend was found for mean nasal cortical thickness values. These results appear to be consistent with bone mineral accrual trend in growing patients^{30,45} and with clinical findings of

increased skeletal maturation in postpubertal subjects (MPS stages 4 and 5), whereas prepubertal subjects (MPS stage 1 and 2) and early pubertal subjects (MPS stage 3) usually show lower degrees of skeletal growth.

A grouping of stages (MPS 1-3 and 4 and 5) were performed to evaluate cortical thickness on the basis of the clinical experience of different levels of skeletal maturation between prepubertal and postpubertal patients (Table III). Two thirds of the patients in MPS stages 1-3 (67.6%) showed a mean palatal cortical thickness of <1 mm, whereas 78.3% of the patients in MPS stages 4 and 5 showed a mean palatal cortical thickness >1 mm. The nasal cortical thickness showed a similar trend, with a lower discrepancy between MPS stages 1-3 (62.16% <1 mm) and 4 and 5 (65.2% >1 mm).

The mean palatal and nasal cortical density were also measured, using gray units as a unit of measure. Mean values were calculated for patients in MPS stages 1-5 (Table III). The palatal cortical density showed a growing trend from MPS stages 1 to 5. MPS stages 1-3 showed similar values, whereas MPS stage 4 showed a significant increase and stage 5 even higher. There was a significant difference in the density of the palatal cortical between MPS stages 1-3 (1272.05 ± 191.13) and stages 4 and 5 (1572.33 ± 274.89) ($P < 0.001$). Once again, these results are consistent with bone mineral accrual trends in growing patients^{30,45} and with clinical findings of greater skeletal maturation in postpubertal subjects (MPS stages 4 and 5). The nasal cortical density showed similar values in MPS stages 1-4, whereas a significant increase was observed in stage 5 (Table V). There was a significant difference in nasal cortical density between MPS stages 1-3 (1428.09 ± 198.97) and stages 4 and 5 (1597.97 ± 267.75) ($P < 0.001$).

Mean palatal medullary density was also evaluated (Table VI). Great standard deviation values were found, with great differences between values in patients in the same MPS stage and within the same patient. A 1-way ANOVA test revealed no statistically significant differences in mean density between groups.

The mean palatal and nasal cortical density was compared in each MPS stage (Fig 6). A significant difference was found in MPS stages 1-3 ($P < 0.05$), whereas no statistical differences were found for stages 4 and 5.

This study has some limitations. First, no grouping based on sex or skeletal type (brachyfacial vs dolichofacial) was performed. Differences between sexes, especially in postpubertal patients, could be expected. Similarly, brachyfacial patients could show higher cortical bone density and thickness values. Therefore, these differences could be investigated in future studies. Furthermore, bone density was measured in gray density units. This unit of measure is not absolute and can differ

from 1 CBCT unit to another,³⁷ so results from this study are not directly comparable with other values present in the literature. Nevertheless, because all the CBCT scans were taken by the same CBCT unit, a qualitative assessment of the bone density trend throughout the different maturation stages was possible. Furthermore, to date, the literature has not given a CT HU reference value to predict the primary stability of miniscrews.

The results of this study have multiple clinical implications. The marked increase in palatal cortical thickness and density found for MPS stages 4 and 5 suggest a higher probability of primary stability in these patients, whereas patients in MPS stages 1-3 are expected to show a lower success rate. To overcome the risk of miniscrew failure because of the inferior thickness and quality of the palatal cortical bone found in subjects at MPS stages 1-3, a solution could be found in the density of the nasal cortical bone. The results of this study show a significant difference between the nasal cortical bone density and the palatal cortical bone density, with higher mean values in MPS stages 1-3. This suggests that a bicortical insertion might be indicated in prepubertal patients to increase primary stability, especially when higher orthodontic forces are required. Furthermore, cortical drilling does not appear to be recommendable, as it could increase the risk of failure in these patients.

In contrast, bicortical insertion can be challenging during miniscrew insertion, especially in late adolescents and young adults because of high insertion torque. This clinical finding appears to be sustained by the results of this present study: higher palatal (1639.85 ± 303.25) and nasal (1681.30 ± 323.56) cortical bone density is found in patients in MPS stage 5. The current literature has not investigated the thickness and density of the nasal cortical bone: the miniscrew design and resistance to insertion torque for patients in MPS stage 5 requiring a bicortical insertion could be revised considering the findings of high nasal cortical density.

Furthermore, these results might also be useful for the orthodontic treatment planning of other conditions and procedures than miniscrews insertion. For example, knowing that the cortical bone density is lower in subjects at MPS stages 1-3 could validate an earlier intervention in the treatment of impacted teeth, preventing the development of abnormal root morphology because of the obstruction of the alveolar bone.⁴⁶

CONCLUSIONS

- MPS stages 1-3 show lower palatal cortical bone density and thickness degrees, whereas nasal cortical bone density shows higher values.

- MPS stages 4 and 5 show higher degrees of palatal and nasal cortical bone density and thickness, with stage 5 presenting the highest values for all the variables.
- Medullary bone density shows great standard deviation values with great differences among values between patients in the same MPS stage and within the same patient; no conclusive results were found.

AUTHOR CREDIT STATEMENT

Camilla Braga contributed to conceptualization and original draft preparation; Lucia Pozzan contributed to formal analysis and original draft preparation; Carlo Ciotola contributed to investigation; Chiara Viganoni contributed to manuscript review and editing; Lucio Torrelli contributed to formal analysis; and Luca Contardo contributed to conceptualization and supervision.

REFERENCES

1. Buschang PH, Carrillo R, Ozenbaugh B, Rossouw PE. 2008 survey of AAO members on miniscrew usage. *J Clin Orthod* 2008;42:513-8.
2. Bock NC, Ruf S. Skeletal anchorage for everybody? a questionnaire study on frequency of use and clinical indications in daily practice. *J Orofac Orthop* 2015;76(113-24):126-8.
3. Meeran NA, Venkatesh KG, Jaseema Parveen MF. Current trends in miniscrew utilization among Indian orthodontists. *J Orthod Sci* 2012;1:46-50.
4. Kyung HM, Park HS, Bae SM, Sung JH, Kim IB. Development of orthodontic micro-implants for intraoral anchorage. *J Clin Orthod* 2003;37:321-8; quiz 314.
5. Ludwig B, Glasl B, Bowman SJ, Wilmes B, Kinzinger GS, Lisson JA. Anatomical guidelines for miniscrew insertion: palatal sites. *J Clin Orthod* 2011;45:433-41; quiz 467.
6. Park HS, Kwon TG, Sung JH. Nonextraction treatment with micro-screw implants. *Angle Orthod* 2004;74:539-49.
7. Cha BK, Lee YH, Lee NK, Choi DS, Baek SH. Soft tissue thickness for placement of an orthodontic miniscrew using an ultrasonic device. *Angle Orthod* 2008;78:403-8.
8. Papageorgiou SN, Zogakis IP, Papadopoulos MA. Failure rates and associated risk factors of orthodontic miniscrew implants: a meta-analysis. *Am J Orthod Dentofacial Orthop* 2012;142:577-95.e7.
9. Kang S, Lee SJ, Ahn SJ, Heo MS, Kim TW. Bone thickness of the palate for orthodontic mini-implant anchorage in adults. *Am J Orthod Dentofacial Orthop* 2007;131(4 Suppl):S74-81.
10. Wehrbein H. Bone quality in the midpalate for temporary anchorage devices. *Clin Oral Implants Res* 2009;20:45-9.
11. Kim YH, Yang SM, Kim S, Lee JY, Kim KE, Gianelly AA, et al. Midpalatal miniscrews for orthodontic anchorage: factors affecting clinical success. *Am J Orthod Dentofacial Orthop* 2010;137:66-72.
12. Bernhart T, Vollgruber A, Gahleitner A, Dörtbudak O, Haas R. Alternative to the median region of the palate for placement of an orthodontic implant. *Clin Oral Implants Res* 2000;11:595-601.
13. King KS, Lam EW, Faulkner MG, Heo G, Major PW. Vertical bone volume in the paramedian palate of adolescents: a computed tomography study. *Am J Orthod Dentofacial Orthop* 2007;132:783-8.
14. Farnsworth D, Rossouw PE, Ceen RF, Buschang PH. Cortical bone thickness at common miniscrew implant placement sites. *Am J Orthod Dentofacial Orthop* 2011;139:495-503.
15. Garn SM, McCreery LD. Variability of postnatal ossification timing and evidence for a "dosage" effect. *Am J Phys Anthropol* 1970;32:139-44.
16. Usui T, Uematsu S, Kanegae H, Morimoto T, Kurihara S. Change in maximum occlusal force in association with maxillofacial growth. *Orthod Craniofac Res* 2007;10:226-34.
17. Pancherz H. Temporal and masseter muscle activity in children and adults with normal occlusion. An electromyographic investigation. *Acta Odontol Scand* 1980;38:343-8.
18. Raadsheer MC, Kiliaridis S, Van Eijden TM, Van Ginkel FC, Prah Andersen B. Masseter muscle thickness in growing individuals and its relation to facial morphology. *Arch Oral Biol* 1996;41:323-32.
19. Braun S, Hnat WP, Freudenthaler JW, Marcotte MR, Hönigle K, Johnson BE. A study of maximum bite force during growth and development. *Angle Orthod* 1996;66:261-4.
20. Han S, Bayome M, Lee J, Lee YJ, Song HH, Kook YA. Evaluation of palatal bone density in adults and adolescents for application of skeletal anchorage devices. *Angle Orthod* 2012;82:625-31.
21. Johnston FE, Hufham HP Jr, Moreschi AF, Terry GP. Skeletal maturation and cephalofacial development. *Angle Orthod* 1965;35:1-11.
22. Hägg U, Taranger J. Maturation indicators and the pubertal growth spurt. *Am J Orthod* 1982;82:299-309.
23. Fishman LS. Chronological versus skeletal age, an evaluation of craniofacial growth. *Angle Orthod* 1979;49:181-9.
24. Perinetti G, Contardo L. Reliability of growth indicators and efficiency of functional treatment for skeletal Class II malocclusion: current evidence and controversies. *BioMed Res Int* 2017;2017:1367691.
25. Perinetti G, Sbardella V, Contardo L. Diagnostic reliability of the third finger middle phalanx maturation (MPM) method in the identification of the mandibular growth peak. *Eur J Orthod* 2017;39:194-201.
26. Schwartz-Dabney CL, Dechow PC. Variations in cortical material properties throughout the human dentate mandible. *Am J Phys Anthropol* 2003;120:252-77.
27. Deguchi T, Nasu M, Murakami K, Yabuuchi T, Kamioka H, Takano-Yamamoto T. Quantitative evaluation of cortical bone thickness with computed tomographic scanning for orthodontic implants. *Am J Orthod Dentofacial Orthop* 2006;129:721.e7-12.
28. Samrit V, Kharbanda OP, Duggal R, Seith A, Malhotra V. Bone density and miniscrew stability in orthodontic patients. *Aust Orthod J* 2012;28:204-12.
29. Migliorati M, Benedicenti S, Signori A, Drago S, Barberis F, Tournier H, et al. Miniscrew design and bone characteristics: an experimental study of primary stability. *Am J Orthod Dentofacial Orthop* 2012;142:228-34.
30. Weaver CM, Gordon CM, Janz KF, Kalkwarf HJ, Lappe JM, Lewis R, et al. The National Osteoporosis Foundation's position statement on peak bone mass development and lifestyle factors: a systematic review and implementation recommendations. *Osteoporos Int* 2016;27:1281-386.
31. Turkyilmaz I, Ozan O, Yilmaz B, Ersoy AE. Determination of bone quality of 372 implant recipient sites using Hounsfield unit from

- computerized tomography: a clinical study. *Clin Implant Dent Relat Res* 2008;10:238-44.
32. Chang CJ, Lin WC, Chen MY, Chang HC. Evaluation of total bone and cortical bone thickness of the palate for temporary anchorage device insertion. *J Dent Sci* 2021;16:636-42.
 33. Shah AH, Behrents RG, Kim KB, Kyung HM, Buschang PH. Effects of screw and host factors on insertion torque and pullout strength. *Angle Orthod* 2012;82:603-10.
 34. Cassetta M, Giansanti M, Di Mambro A, Calasso S, Barbato E. Accuracy of two stereolithographic surgical templates: a retrospective study. *Clin Implant Dent Relat Res* 2013;15:448-59.
 35. Cassetta M, Stefanelli LV, Giansanti M, Di Mambro A, Calasso S. Depth deviation and occurrence of early surgical complications or unexpected events using a single stereolithographic surgical guide. *Int J Oral Maxillofac Surg* 2011;40:1377-87.
 36. Arisan V, Karabuda ZC, Avsever H, Özdemir T. Conventional multi-slice computed tomography (CT) and cone-beam CT (CBCT) for computer-assisted implant placement. Part I: relationship of radiographic gray density and implant stability. *Clin Implant Dent Relat Res* 2013;15:893-906.
 37. Song YY, Cha JY, Hwang CJ. Mechanical characteristics of various orthodontic mini-screws in relation to artificial cortical bone thickness. *Angle Orthod* 2007;77:979-85.
 38. Merheb J, Van Assche N, Coucke W, Jacobs R, Naert I, Quirynen M. Relationship between cortical bone thickness or computerized tomography-derived bone density values and implant stability. *Clin Oral Implants Res* 2010;21:612-7.
 39. Pithon MM, Nojima MG, Nojima LI. Primary stability of orthodontic mini-implants inserted into maxilla and mandible of swine. *Oral Surg Oral Med Oral Pathol Oral Radiol* 2012;113:748-54.
 40. Motoyoshi M, Inaba M, Ono A, Ueno S, Shimizu N. The effect of cortical bone thickness on the stability of orthodontic mini-implants and on the stress distribution in surrounding bone. *Int J Oral Maxillofac Surg* 2009;38:13-8.
 41. Motoyoshi M, Yoshida T, Ono A, Shimizu N. Effect of cortical bone thickness and implant placement torque on stability of orthodontic mini-implants. *Int J Oral Maxillofac Implants* 2007;22:779-84.
 42. Wilmes B, Rademacher C, Olthoff G, Drescher D. Parameters affecting primary stability of orthodontic mini-implants. *J Orofac Orthop* 2006;67:162-74.
 43. Marquezan M, Souza MM, Araújo MT, Nojima LI, Nojima C. Is miniscrew primary stability influenced by bone density? *Braz Oral Res* 2011;25:427-32.
 44. Ichinohe M, Motoyoshi M, Inaba M, Uchida Y, Kaneko M, Matsuike R, et al. Risk factors for failure of orthodontic mini-screws placed in the median palate. *J Oral Sci* 2019;61:13-8.
 45. Bailey DA, McKay HA, Mirwald RL, Crocker PR, Faulkner RA. A six-year longitudinal study of the relationship of physical activity to bone mineral accrual in growing children: the university of Saskatchewan bone mineral accrual study. *J Bone Miner Res* 1999;14:1672-9.
 46. Wu G, He S, Chi J, Sun H, Ye H, Bhikoo C, et al. The differences of root morphology and root length between different types of impacted maxillary central incisors: a retrospective cone-beam computed tomography study. *Am J Orthod Dentofacial Orthop* 2022;161:548-56.