

Maxillary distalization by a rearrangement of the Leaf Expander® screw combined with palatal miniscrews: A case report on the MaXimo Appliance

Perinetti, Giuseppe¹; Alex, Bruno²; Paolo, Tonini²

¹ Private practice, Nocciano (PE), Italy

² Dental technician, Ortotec Orthodontic Laboratory, Tricesimo (UD), Italy

ABSTRACT

Introduction: This case report describes the treatment of a crowded dental Class II malocclusion in 13 years, 2 months female patient. Maxillary distalization was achieved by a novel compliance-free appliance referred to as MaXimo, which was built by a rearrangement of the Leaf Expander® screw having palatal miniscrews as the anchorage core.

Case Presentation: Pre-treatment, post-treatment and 1-year follow-up records are shown. No side effects, breakage of the appliance or loss of miniscrews was encountered. The active distalization phase lasted 14 months, while the whole treatment, including the use of multibrackets appliance, lasted 25 months. A significant spontaneous distal drifting of the premolars and canines was seen. The treatment outcomes proved to be stable at the follow-up with acceptable aesthetic and functional results.

Conclusion: The MaXimo appliance proved to be efficient and of easy management, and its use may be recommended when distalization of the maxillary dentition is required. Being mostly assembled by the manufacturer, the MaXimo appliance is also cheap and of easy construction.

Perinetti G, Bruno A, Tonini P. Maxillary distalization by a rearrangement of the Leaf Expander® screw combined with palatal miniscrews: A case report on the MaXimo Appliance. *South Eur J Orthod Dentofac Res.* 2019;6(2):40-44.

April 02, 2019; Revised: September 07, 2019; Published: October 14, 2019

INTRODUCTION

Among the most frequent malocclusions is Class II. When the patients present with a skeletal Class II malocclusion and treatment may be delivered at proper timing, functional treatment is preferable because of the orthopedic outcome.^{1,2} However, patients may have a dental Class II malocclusion in combination with a skeletal Class I pattern, or a mild skeletal Class II malocclusion, or even a relevant skeletal Class II malocclusion but refusing surgery. In all of these cases, and with an exception for extraction treatments, distalization of the maxillary dentition remains the only option, even regardless of the potential aesthetic impact.³

Anchorage is still considered one of the main problems when distalizing the maxillary dentition. Recent evidence has shown that classical distalizing techniques using the intra-oral appliance without any skeletal anchorage may produce an anchorage loss at the incisors, equal or even higher than the amount of molar distalization.^{4,5} On the contrary, intra-oral appliances anchored on miniscrews do not show anterior loss of anchorage.^{4,5}

In this regard, the use of skeletal anchorage through palatal miniscrews⁶ is becoming popular in orthodontics. With proper components, palatal appliances may be constructed and mounted at the palatal level from miniscrews to teeth that need to be moved.⁶⁻⁸ Advantages offered by palatal anchorage at the anterior paramedian area^{6,9} reside in the availability of an ideal insertion site without roots, major blood vessels or nerves, and with an acceptable gingival thickness.⁶ Moreover, anterior palatal miniscrews do not need to be removed and reinserted during the

Corresponding Author:

Perinetti Giuseppe

Via San Lorenzo 69/1,

65010 Nocciano (PE), Italy.

e-mail: G.Perinetti@yahoo.com

treatment, as it may happen for the vestibular ones. Specifically, for distalization treatment, the same distalizing appliance may easily be looked after the end of the active phase to become an efficient anchorage system during the retraction of the rest of the dentition. Several appliances anchored on palatal miniscrews are available for the molar distalization such as distal-jet,⁷ distal screw,⁸ distal slider¹⁰ and modified frog¹¹. All of these appliances are based on dedicated components thus suffering a relatively high production cost.

The Leaf Expander® screw (Leone Orthodontics and Implantology, Sesto Fiorentino [FI], Italy) has been designed for slow and maxillary expansion.¹² However, its constant force release by a discontinued activation makes it a good candidate for a distalizing tool, where optimal force delivery for tooth movement has to be uninterrupted and constant.¹³ This case report describes

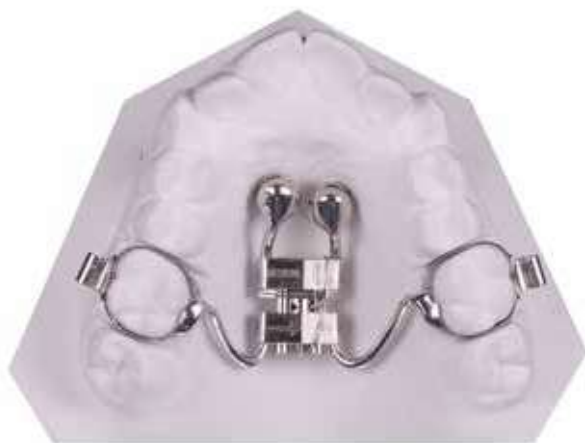

Figure 1. The MaXimo appliance (reprinted with permission from Perinetti et al.¹⁴)

the treatment of a crowded dental Class II malocclusion where maxillary distalization was achieved by a novel compliance-free appliance referred to as 'MaXimo' (Figure 1), that has been constructed by rearranging a Leaf Expander® screw having palatal miniscrews as the anchorage core. Part of this clinical case has been previously reported.¹⁴

CASE PRESENTATION

A 13 years, 2 months old female (Figure 2) presented with a dentoskeletal Class I malocclusion, a bilateral half-cusp Class II molar relationship, and increased overbite and overjet, along with a noteworthy dental crowding in both arches. Her medical history was not contributory. Soft tissue profile and cephalometric analysis showed a very slight tendency towards a skeletal Class II malocclusion (ANB, 3.1°; Wits appraisal, 2.3 mm) associated to a bi-maxillary retrusion (A to N perp., -1.0 mm and Pog to N perp., -5.4 mm) (Figure 2; Table 1). A reduced vertical growth pattern (SN to GoGn, 25.8°) was also seen with no major

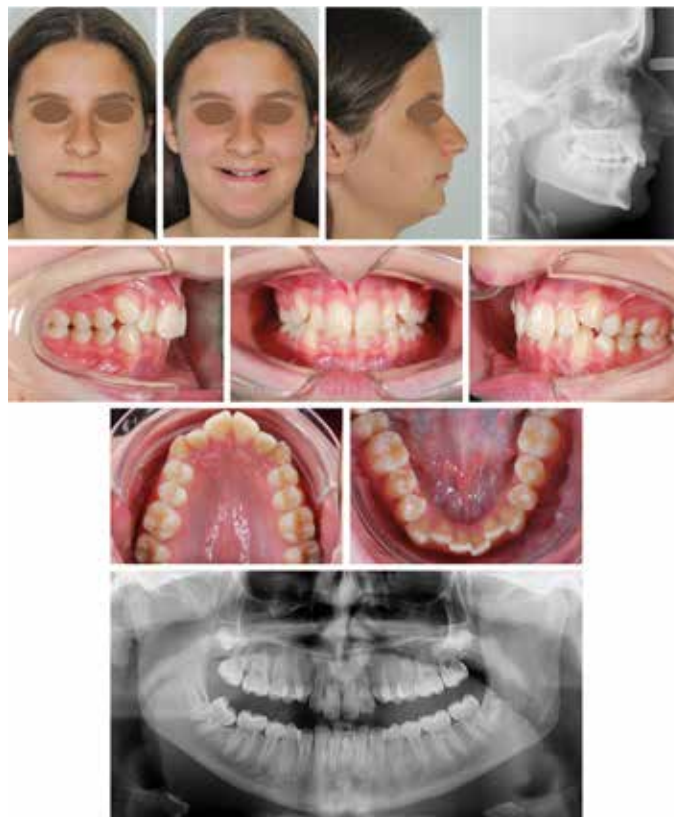

Figure 2. The 13 years, 2 months old female patient with dental Class II malocclusion, increased overjet and overbite before treatment (modified with permission from Perinetti et al.¹⁴).

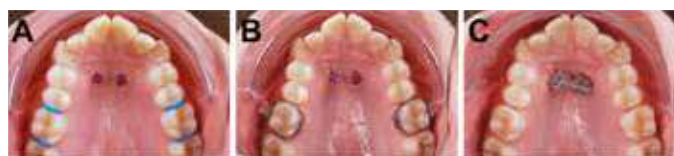

Figure 3. A, palatal miniscrews insertion; B, bands adapted on first molars; C, abutments placed over the screw heads (reprinted with permission from Perinetti et al.¹⁴).

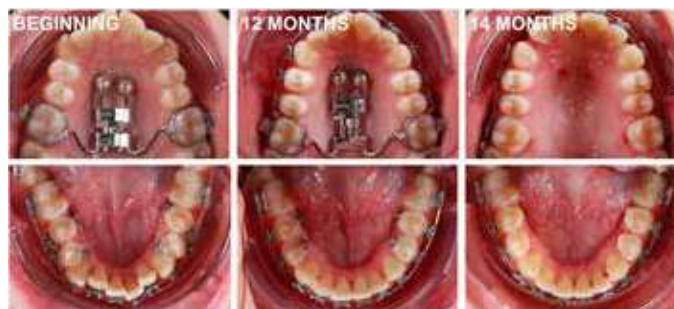

Figure 4. Maxillary occlusal views of treatment progress from beginning to 14 months of treatment when the MaXimo and miniscrews were removed (modified with permission from Perinetti et al.¹⁴).

skeletal transverse maxillary deficiency (Figure 2). A panoramic radiograph revealed the presence of all of the third molars and no other anomalies. At the moment the patient presented second molars were fully erupted (Figure 2). Orthodontic treatment was started immediately by means of a bilateral MaXimo appliance (900 g, code A2704-09, Leone Orthodontics and Implantology,) in combination with multibracket appliance. Written informed consent was obtained from the parents of the patient for publication of this case report and accompanying images.

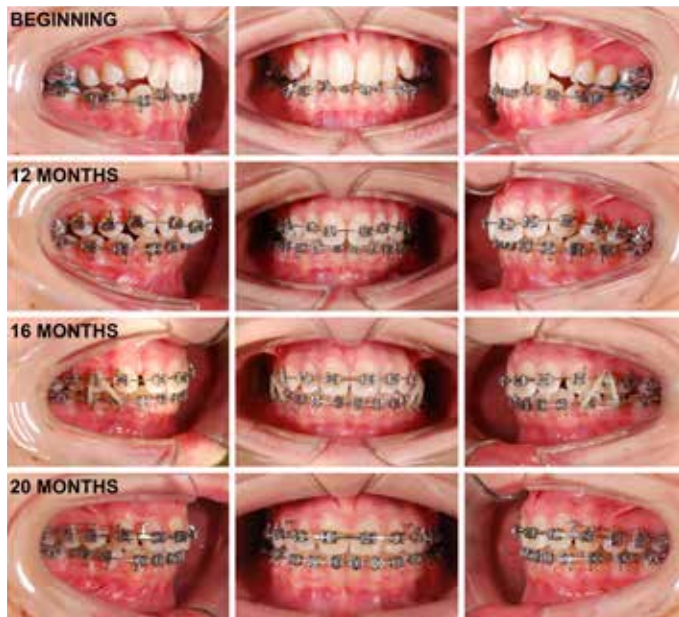

Figure 5. Frontal and lateral views of treatment progress from beginning to 20 months of treatment (modified with permission from Perinetti et al.¹⁴).

At the first visit, 8-mm-long miniscrews (Code 1101A2308, Orthoeasy, Forestadent, Pforzheim, Germany) were inserted into the palate according to previous recommendations,⁶ and impression was taken by silicone material after having adapted bands on first molars and abutments (Orthoeasy) placed over screw heads¹¹ (Figure 3). Subsequently, the MaXimo appliance carrying a 6-mm screw with 900 gr force (Model A2704-10, Leone) was tied with ligature wire to both miniscrews and with glass-ionomer cement on the first molars according to previous reports.¹¹ The MaXimo appliance was activated immediately (Figure 4).

Full fixed orthodontic treatment was carried out by an MBT 0.22-inch-slot straight-wire multi-bracket appliance (Optimus, Effedental, Barbeano di Spilimbergo [PN]) that was mounted at the mandibular dentition along with the MaXimo appliance. During the initial phase of leveling and alignment, lower incisor stripping was performed to reduce anterior crowding by controlling excessive inclination to the mandibular plane (Figures 4, 5). At 12 months of treatment, distal drifting of

the maxillary premolars and molars was evident although not complete, and bonding to the upper arch was executed (Figures 4, 5). At 14 months of treatment, the MaXimo appliance was removed along with the palatal miniscrews. Bands on the maxillary molars were replaced by bonded tubes and maxillary second molars were also bonded. During the active distalization phase, the MaXimo appliance was activated by 2-4 turns (0.2-0.4 mm) per month, and no breakage, pain or other undesired side effects was encountered. At 16 months of treatment, full-

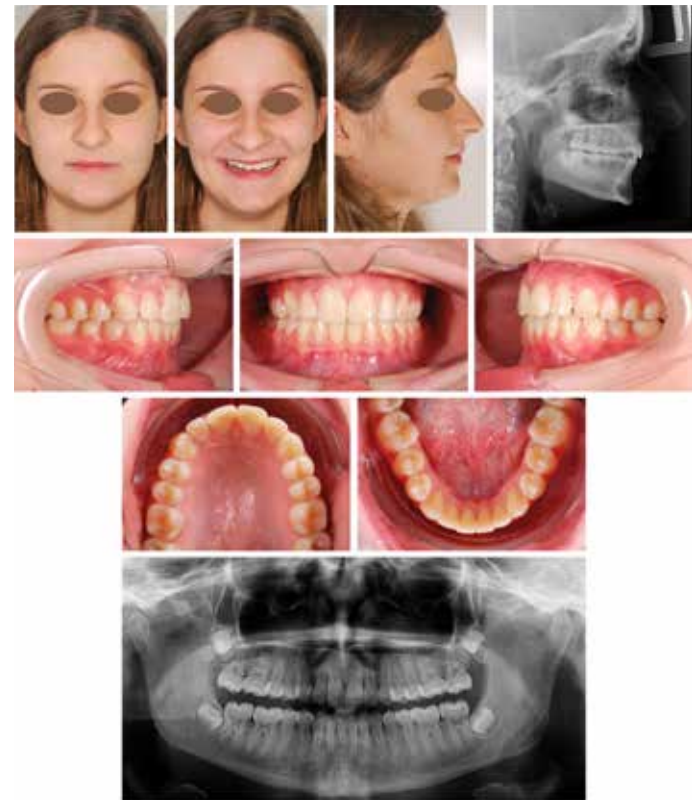

Figure 6. Patient after 25 months of treatment when she was 15 years and 5 months old.

time posterior intermaxillary elastics were used to improve premolar intercuspation (Figure 5). At 20 months of treatment, tie-backs (utilizing 0.019x0.025-inch SS archwire) were applied to close anterior spaces (Figure 5), while intermaxillary elastics were worn at night until the end of treatment. The whole treatment lasted 25 months with the achievement of first dental Class on both sides, good interdigitation with reduction of the overbite and overjet. Maxillary and mandibular midlines remained centered between each other and with the face. Panoramic radiograph showed good root parallelism (Figure 6). Finally, Essix retainers were delivered to the patient who was instructed to wear at night. The cephalometric analysis at the end of treatment (Table 1) showed no significant changes in the sagittal or vertical bone relationship, while both overbite and overjet reduced (1.5

mm and 2.4 mm, respectively). At the end of the orthodontic treatment, superimposition on the anterior cranial base¹⁵ showed a very minimal skeletal and soft-tissue changes (Figure 7A). The regional mandibular superimposition¹⁶ demonstrated a slight molar extrusion while incisors underwent a clinically negligible inclination as reported above (Figure 7B). The regional maxillary superimposition¹⁶ demonstrated a clear molar distalization along with incisor retraction of about 2 mm. In particular, molars underwent minimal distal tipping of 5.1°, while incisors increased their inclination relative to the maxillary plane as reported above (Figure 7B).

Finally, stable results were seen at the 12 months follow-up in

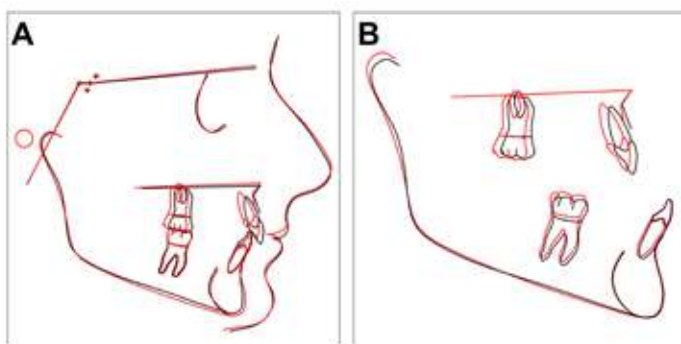


Figure 7A and 7B. A. Superimposition of pre-treatment (black), post-treatment (red) cephalometric tracings on stable structures of the anterior cranial base. B. Regional superimposition of cephalometric tracings on maxilla and mandible.

terms of intercuspatation and dental alignment (Figure 8).

DISCUSSION

The present case shows the noteworthy efficiency of a rigid distalizing appliance such as the MaXimo in combination with palatal anchorage. Distalization was effective even in the presence of unerupted third molar and no side effects or breakage was encountered by the patient, to which minimal compliance was required.

The use of palatal miniscrews offers several advantages, for instance, leveling and alignment of the maxillary arch to proceed simultaneously with the distal movement. Another important aspect relates to the spontaneous distal drifting of the premolars following the molar distalization. The previous evidence^{5,8} has shown up to 50% of spontaneous premolar distalization when these teeth do not have obstacles (i.e. vestibular miniscrew) during movement. In the present case, a premolar drifting has been seen in association with an almost complete alignment of the canines even before the multibrackets appliance was placed at the maxillary arch at 12 months of treatment (Figure 5). Therefore, distal drifting may occur in canines to some extent

and it would be advantages in cases with maxillary crowding. Even though in the present case distal drifting of the premolars and canine was almost complete (Figure 5), this outcome remains not entirely predictable;^{5,8} therefore, a specific treatment stage has to be dedicated to the full distalization of the canines and premolars before the en-mass retraction of the incisors.

The timing of intervention for maxillary molar distalization in relation to the presence of second and third molars has been a matter of debate over the last few decades.¹⁷⁻²² Before the advent of skeletal anchorage, a recommendation was to distalize before the eruption of the second molars,¹⁹ even though recent evidence¹⁸ has shown that the presence of erupted second molars (eventually along with unerupted third molars) would not have major effects on the degree of distalization (irrespective of the use of skeletal anchorage). Considering this piece of evidence¹⁸ in combination with the use of skeletal anchorage, current

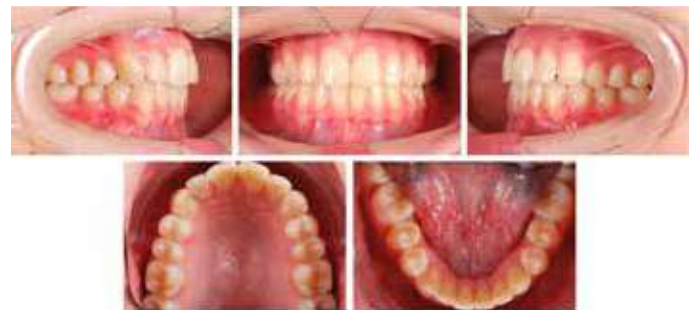

Figure 8. Patient after 12 months of follow-up when she was 15 years and 5 months old.

Table 1. Cephalometric data.

Ages at pre-treatment and post-treatment were 13 years, 2 months and 15 years, 5 months, respectively. Norms retrieved according to the following analyses:²⁴ a, Riedel; b, Mcnamara; c, Wits appraisal; d, Burnstone.

Parameter	Pre-treatment	Post-treatment	Norms
SNA angle	83.6°	82.7°	82.0° (a)
SNB angle	80.5°	79.8°	80.0° (a)
A to Nasion perp.	-1.0 mm	-1.2 mm	1.1 mm (b)
Pog to Nasion perp.	-5.4 mm	-4.1 mm	-0.3 mm (b)
ANB angle	3.1°	2.9°	2.0 (a)
Wits appraisal	2.3 mm	2.4 mm	0.0 mm (c)
SN to GoGn	25.8°	26.1°	31.7° (a)
+1 to Palatal plane	106.3°	108.6	111.0° (d)
-1 to mandibular plane	95.8°	98.4°	93.1° (a)
+1 to A-Pog	4.9 mm	2.8 mm	5.3 mm (b)
-1 to A-Pog	0.1 mm	0.3 mm	2.3 mm (b)
Overbite	4.5 mm	1.5 mm	--
Overjet	4.7 mm	2.4 mm	--

recommendation^{17,23} would be to distalize after the eruption of second molars to avoid undesired side effects, such as root resorption of the first molars.²² In this regard, the MaXimo appliance delivers recommended force for molar distalization when second molars have erupted.²¹ Moreover, as seen herein, unerupted third molars do not need to be extracted,^{17,23} although the available space for their eruption may be reduced after maxillary distalization.²⁰ No major tipping of first molars has been encountered, as reported previously for other appliances.^{4,5,8}

During treatment oral hygiene was kept optimal and patient's compliance was limited to the use of vertical intermaxillary elastics to improve intercuspation and not for distalizing the maxillary dentition (having the lower incisor proclination as

an undesired side effect). No breakage or loss of the miniscrews was experienced. Finally, being mostly assembled by the manufacturer, it has a comfortable construction and cheapness.

CONCLUSION

Although future studies are warranted to elucidate the merits of the MaXimo appliance fully, its use appears recommended when distalization of the maxillary dentition is desired.

CONFLICT OF INTEREST

The authors declare that there is no conflict of interest regarding the publication of this paper.

REFERENCES

- Perinetti G, Primozic J, Franchi L, Contardo L. Treatment Effects of Removable Functional Appliances in Pre-Pubertal and Pubertal Class II Patients: A Systematic Review and Meta-Analysis of Controlled Studies. *PLoS One*. 2015;10:e0141198.
- Perinetti G, Primozic J, Furlani G, Franchi L, Contardo L. Treatment effects of fixed functional appliances alone or in combination with multibracket appliances: A systematic review and meta-analysis. *Angle Orthod*. 2015;85:480-92.
- Perinetti G. Distalization of the maxillary dentition: Lights and shadows between old and new technologies. *South Eur J Orthod Dentofac Res*. 2018;5:1.
- Mohamed RN, Basha S, Al-Thomali Y. Maxillary molar distalization with miniscrew-supported appliances in Class II malocclusion: A systematic review. *Angle Orthod*. 2018;88:494-502.
- Grec RH, Janson G, Branco NC, Moura-Grec PG, Patel MP, Castanha Henriques JF. Intraoral distalizer effects with conventional and skeletal anchorage: a meta-analysis. *Am J Orthod Dentofacial Orthop*. 2013;143:602-15.
- Ludwig B, Glasl B, Bowman SJ, Wilmes B, Kinzinger GS, Lisson JA. Anatomical guidelines for miniscrew insertion: palatal sites. *J Clin Orthod*. 2011;45:433-41.
- Bowman SJ. The Horseshoe Jet for miniscrew-supported molar distalization. *J Clin Orthod*. 2018;52:196-218.
- Caprioglio A, Cafagna A, Fontana M, Cozzani M. Comparative evaluation of molar distalization therapy using pendulum and distal screw appliances. *Korean J Orthod*. 2015;45:171-9.
- Holm M, Jost-Brinkmann PG, Mah J, Bumann A. Bone thickness of the anterior palate for orthodontic miniscrews. *Angle Orthod*. 2016;86:826-31.
- Wilmes B, Drescher D. Application and effectiveness of the Beneslider: a device to move molars distally. *World J Orthod*. 2010;11:331-40.
- Ludwig B, Glasl B, Kinzinger GS, Walde KC, Lisson JA. The skeletal frog appliance for maxillary molar distalization. *J Clin Orthod*. 2011;45:77-84; quiz 91.
- Lanteri C, Beretta M, Lanteri V, Gianolio A, Cherchi C, Franchi L. The Leaf Expander for Non-Compliance Treatment in the Mixed Dentition. *J Clin Orthod*. 2016;50:552-60.
- Perinetti G, Contardo L, Franchi L, Baccetti T. The biology of orthodontic tooth movement and the impact of anti-inflammatory drugs. In: McNamara JA, Hatch N, Kapila SD, editors. *Effective and Efficient Orthodontic Tooth Movement*. Craniofacial Growth Series. Center for Human Growth and Development, University of Michigan. Ann Arbor: Needham Press; 2011. p. 117-40.
- Perinetti G, Dal Borgo B, Contardo L, Tonini P, Bruno A. MaXimo: Un nuovo distalizzatore intraorale ancorato su miniviti palatali. *Bollettino di Informazione Leone*. 2016;98:54-62.
- Almeida-Pedrin RR, Almeida MR, Almeida RR, Pinzan A, Ferreira FP. Treatment effects of headgear biteplane and bionator appliances. *Am J Orthod Dentofacial Orthop*. 2007;132:191-8.
- Orthodontics ABo. Case report preparation: Composite tracings. St. Louis; 2007.
- Bowman SJ. Upper-Molar Distalization and the Distal Jet. *J Clin Orthod*. 2016;50:159-69.
- Flores-Mir C, McGrath L, Heo G, Major PW. Efficiency of molar distalization associated with second and third molar eruption stage. *Angle Orthod*. 2013;83:735-42.
- Gianelly AA. Distal movement of the maxillary molars. *Am J Orthod Dentofacial Orthop*. 1998;114:66-72.
- Miclotte A, Grommen B, Lauwereins S, Cadenas de Llano-Perula M, Alqerban A, Verdonck A, et al. The effect of headgear on upper third molars: a retrospective longitudinal study. *Eur J Orthod*. 2017;39:426-32.
- Nienkemper M, Wilmes B, Pauls A, Yamaguchi S, Ludwig B, Drescher D. Treatment efficiency of mini-implant-borne distalization depending on age and second-molar eruption. *J Orofac Orthop*. 2014;75:118-32.
- Al-Junaid S, Acharya P. Bilateral root resorption of maxillary first permanent molars by unerupted second molars associated with orthodontic distalisation. *J Orthod*. 2018;45:198-202.
- Lee YJ, Kook YA, Park JH, Park J, Bayome M, Vaid NR, et al. Short-term cone-beam computed tomography evaluation of maxillary third molar changes after total arch distalization in adolescents. *Am J Orthod Dentofacial Orthop*. 2019;155:191-97.
- Athanasiou AE, editor. *Orthodontic Cephalometry*. London: Mosby-Wolfe; 1995.